

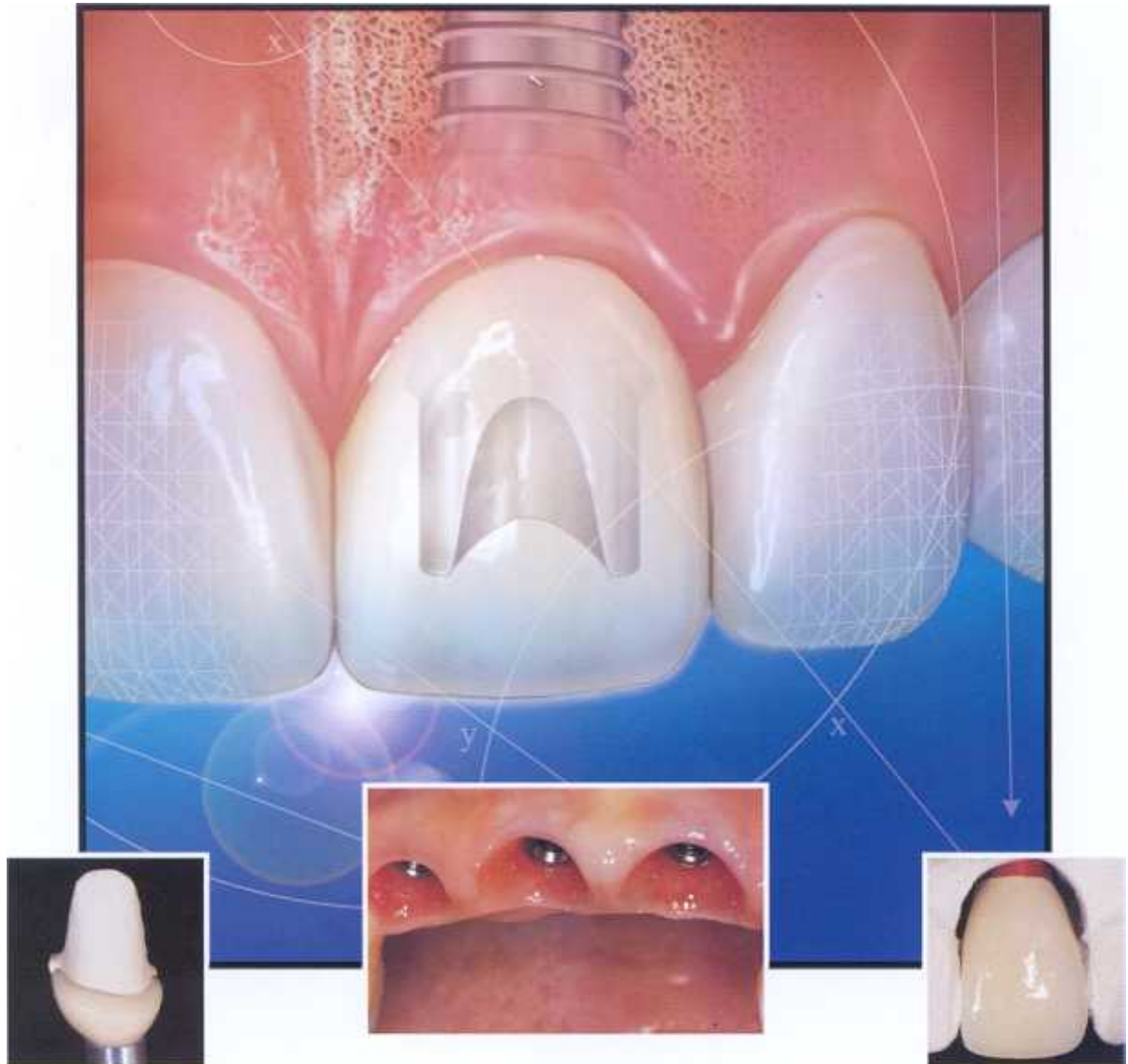# PPAD

## Practical Procedures & AESTHETIC DENTISTRY

Prosthodontics • Periodontics • Endodontics • Research • Laboratory Considerations

VOLUME 4 NO 2

MARCH 2002



- Aesthetic Restorative Options and Implant Site Enhancement Using Orthodontic Extrusion
- Immediate Implant Placement With Immediate Provisional Crown Placement
- Multidisciplinary Approach for Achieving Aesthetics in a Cleft Lip and Palate Patient



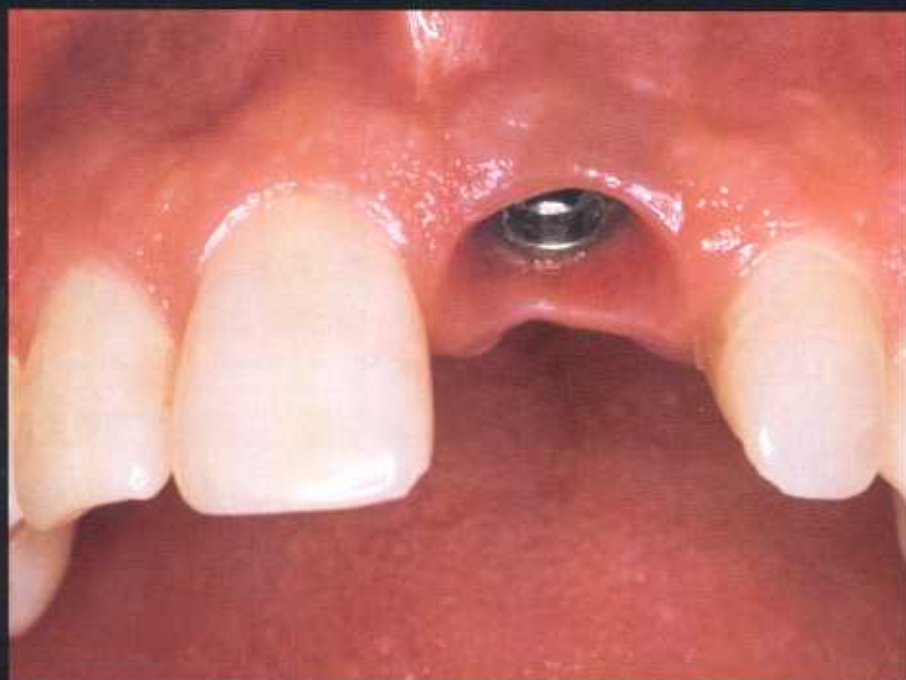A Montage Media Publication

**ADACERP**

MONTAGE MEDIA CORPORATION IS AN  
ADA CERP RECOGNIZED PROVIDER

# GUIDELINES FOR AESTHETIC RESTORATIVE OPTIONS AND IMPLANT SITE ENHANCEMENT: THE UTILIZATION OF ORTHODONTIC EXTRUSION

Maurice A. Salama, DMD\*  
Henry Salama, DMD†  
David A. Garber, DMD‡



*The patient with hopeless, fractured, or missing teeth within the aesthetic zone has posed a tremendous challenge for today's clinician. This article discusses "diagnostic indicators" involved during the evaluation of questionable teeth or edentulous spans prior to treatment planning, as well as the potential adjunctive role of orthodontics for the development of an aesthetic restorative recipient site. The utilization of orthodontic extrusion in combination with atraumatic extraction and immediate implant replacement utilizing a tapered implant system is also highlighted.*

*Key Words: implant, gingival, orthodontic, bone sounding*

\*Assistant Clinical Professor, Department of Periodontology, Medical College of Georgia, School of Dentistry, Atlanta, Georgia; private practice, Atlanta, Georgia.

†Clinical Assistant Professor, Department of Periodontology, University of Pennsylvania, Philadelphia, Pennsylvania; private practice, Atlanta, Georgia.

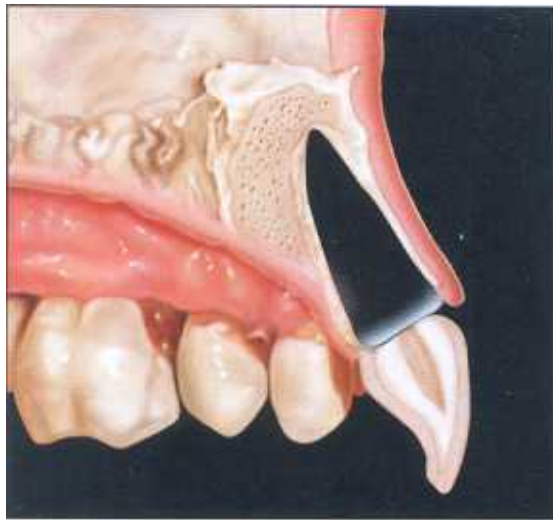‡Clinical Professor, Department of Periodontics, Medical College of Georgia, School of Dentistry, Atlanta, Georgia; private practice, Atlanta, Georgia.

**Maurice A. Salama, DMD**  
1218 West Paces Ferry Road  
Suite 200  
Atlanta, GA 30327

Tel: 404-261-4941

Fax: 404-261-4346

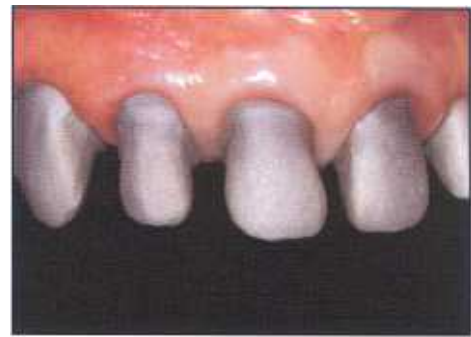E-mail: [goldsteingarber@goldsteingarber.com](mailto:goldsteingarber@goldsteingarber.com)



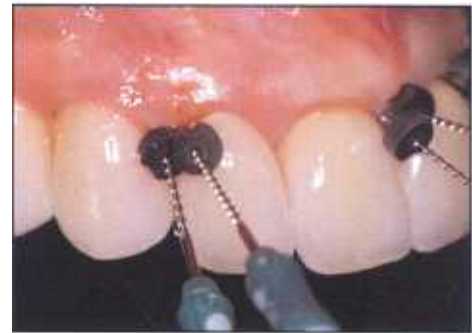**Figure 1.** The implant site consists of the surrounding socket walls of an extracted tooth, the shape of the root, and the continuity of form emerging from the implant leading to the proposed restoration.

While the treatment of hopeless, fractured, or missing teeth has traditionally presented difficulties within the anterior region, one of the primary considerations in deciding on tooth replacement procedures has been a lack of predictability in constructing an aesthetic restoration, particularly following implant therapy. Most clinicians have limited guidance in the evaluation and then selection of the appropriate restorative options in the "aesthetic zone." Recent investigations have focused on the diagnostic evaluation of a site prior to selecting a particular restorative option for tooth replacement (Table). This selection criteria is based upon a thorough evaluation of the alveolar bone surrounding the site, particularly the interproximal bone, which significantly influences individual tooth form and aesthetics (Figures 1 through 4).

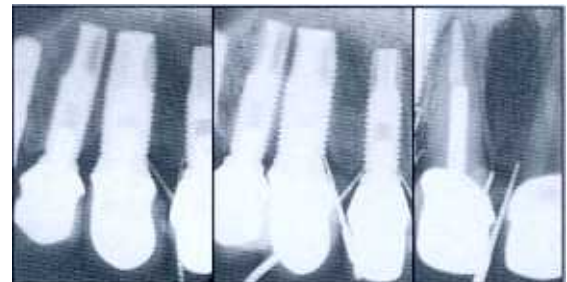
One of the primary reasons for failure in this region has been ineffective or missing "diagnostic indicators" that cause aesthetic tooth replacement selection of a site to be unpredictable. In an attempt to simplify the diagnostic process, the authors defined future restorative sites as: 1) existing edentulous spans (ie, delayed sites), and 2) hopeless teeth prior to planned extractions (eg, immediate sites). During the treatment of a previously extracted tooth in an edentulous span, bone



**Figure 2.** The metal try-in of multiple single units. It is difficult to distinguish between implants and natural tooth abutments.



**Figure 3.** Size 30 endodontic files with rubber stops were used to measure the interproximal peak of bone on the adjacent sites and their distance from the final contact points.



**Figure 4.** Radiographic measurements display the importance of the measurement of the adjacent sites in predicting anticipated soft tissue position interproximally between implants, natural teeth, and pontics.

sounding of the interproximal peaks must be performed, and the labial plate must be located prior to selection of the appropriate restoration (Figures 5 and 6). As described by Tarnow and Kois, as well as Salama et al, the location of the interproximal peak of bone will allow determination of the anticipated quality of the interproximal soft tissues around the restorations.<sup>1-3</sup> The interproximal

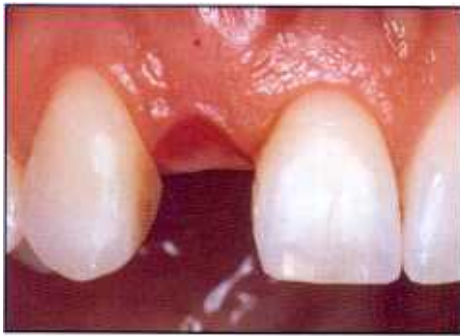

Figure 5. An ovate pontic preparation was performed prior to delayed implant placement.

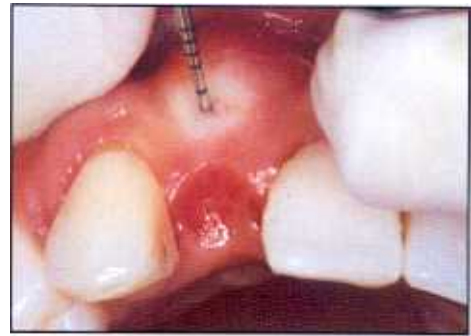

Figure 6. Labial plate and interproximal bone sounding is required prior to implant placement.

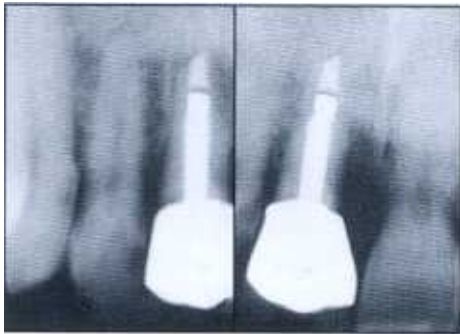


Figure 7. The fractured left central incisor was radiographically observed and a poor prognosis was determined.

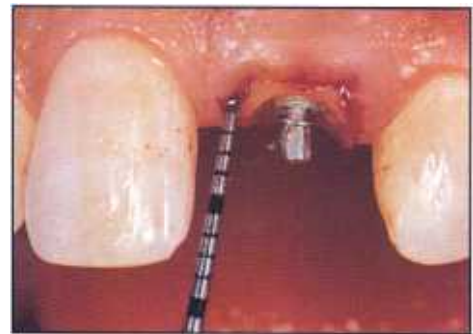

Figure 8. Bone sounding was performed prior to extraction on the hopeless tooth. Adequate bone support for interdental soft tissue response was indicated.

peak of bone has been indirectly utilized in the middle of the contact area to suggest the predictability of papilla around dental implants.<sup>4</sup> Probing of the site adjacent to the proposed implant has also demonstrated efficacy in predicting the postoperative location of the interproximal soft tissue levels.<sup>3</sup> Probing of the interproximal peaks

of bone on the adjacent teeth, implants, or pontic areas should, therefore, facilitate appropriate selection of a proposed restoration. Based upon a variety of clinical data (Table), the preoperative bone sounding measurements should facilitate the selection of an optimal restorative option that corresponds to the surrounding bony

Table

Class	Restorative Environment	Proximity Limitation	Vertical Soft-Tissue Limitations	
			Mean	Range (in mm)
1	Tooth-Tooth	1 mm	1	4.5 to 5
2	Tooth-Pontic	N/A	6.75	4 to 9
3	Pontic-Pontic	N/A	6.5	5 to 9
4	Tooth-Implant	1.5 mm	6.5	4 to 9
5	Implant-Pontic	N/A	5.75	5 to 9
6	Implant-Implant	3 mm	4.5	4 to 7

\*Cumulative data of two test groups: (A) 37 patients with single- and multiple-unit implants placed in the maxillary anterior region and (B) 11 patients who received conventional anterior fixed bridgework with pontics. Vertical soft tissue depth was measured interproximally immediately adjacent to the implants, pontics, and teeth.<sup>3</sup>

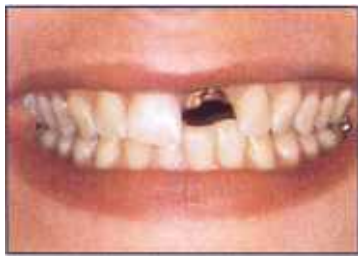

Figure 9. Preoperative facial view demonstrates the presence of a subgingival fracture on the maxillary left central incisor within the lip perimeter and the aesthetic zone.

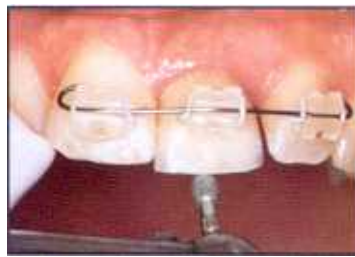

Figure 10. Orthodontic extrusion and occlusal adjustment was performed to enhance the bone and soft tissue dimensions 8 to 12 weeks prior to extraction.

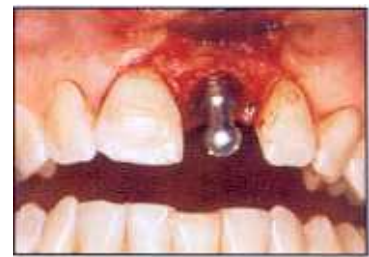

Figure 11. Immediate implant placement was performed following atraumatic extraction utilizing a tapered implant, approximately 5.5 mm in diameter, to replace the extracted central incisor.

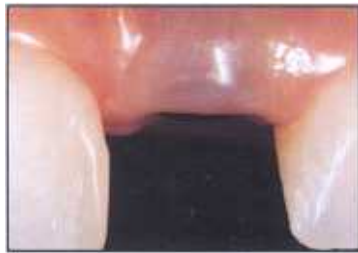

Figure 12. A healing abutment was used for vertical support of the soft tissues. Note the added dimension of soft tissue provided by the orthodontic treatment.

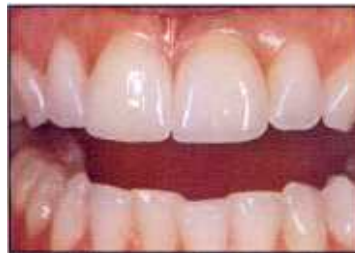

Figure 13. Postoperative facial view demonstrates enhanced aesthetics and surrounding soft tissue health.

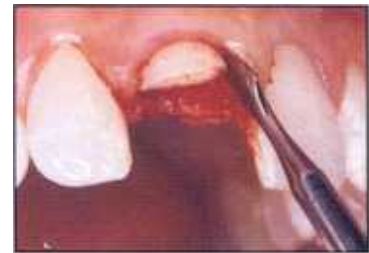

Figure 14. Periostomes are ideal for atraumatic extraction following orthodontic extrusion, as they place no added pressure on the surrounding bony walls.

anatomy of the individual patient.<sup>5</sup> Since many post-operative complications are developed due to poor diagnosis and not from lack of technical expertise, this information will significantly influence the development of an aesthetic result.

Bone sounding is an important aspect of the diagnostic phase during the treatment of teeth that are scheduled for extraction (eg, immediate sites) (Figures 7 and 8). The site can then be evaluated and orthodontically altered if it is determined to be inadequate.<sup>6</sup> Orthodontic tooth movement will allow for a simplified nonsurgical approach to enhancing areas with poor soft tissue levels, recession, or missing papillae with inadequate interproximal peaks of bone prior to extraction and immediate implant placement (Figure 9).

The orthodontic augmentation technique utilizes the remaining attachment apparatus around the hopeless tooth by providing orthodontic tension on the periodontal ligament to manipulate the attachment apparatus in

a vertical direction and thereby relocate the bone and soft tissues coronally to extraction (Figure 10). This technique generally requires approximately 8 to 12 weeks of orthodontic extrusion followed by 4 to 6 weeks of stabilization. The levels of orthodontic forces applied are light

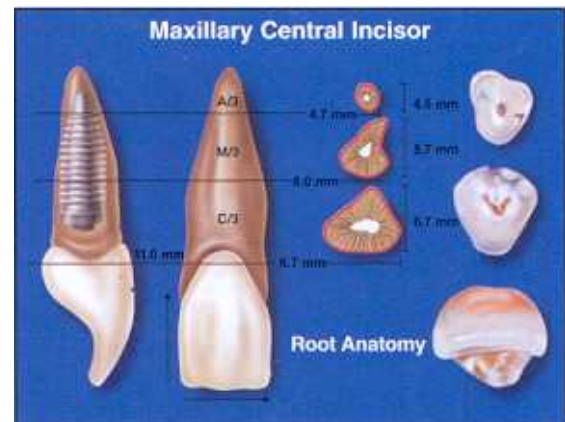
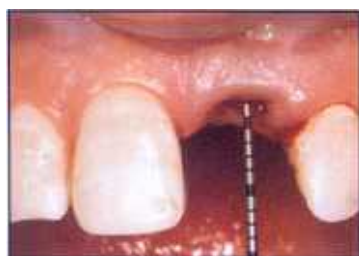
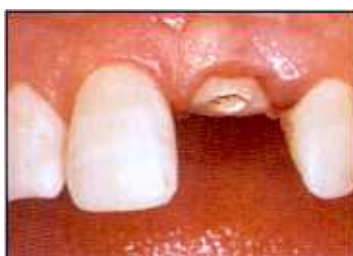
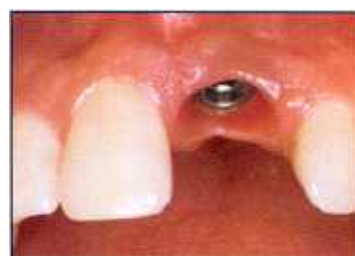Figure 15. Selection of the implant diameters is based upon the anticipated location of the head of the fixture in relation to the mesial distal diameter of the root anatomy.



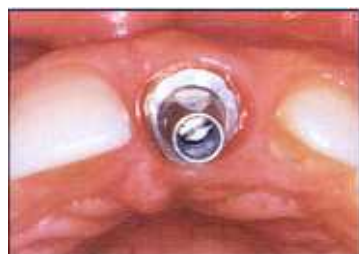**Figure 16.** Following extraction with the periostomes, the implant site is internally and externally reevaluated with a probe.



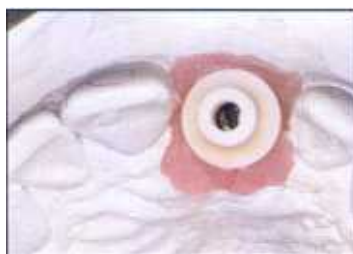**Figure 17.** Utilizing a temporary cylinder, a healing abutment was customized to reestablish the proper subgingival contours and support the interdental papillae and labial gingiva.



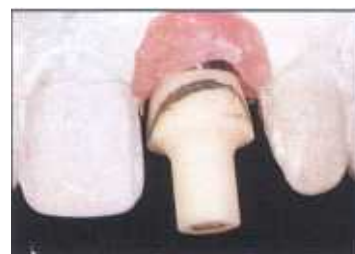**Figure 18.** Five months postoperative healing and maturation of the soft tissue. Note the health and contour of the soft tissue that was formed utilizing a customized healing abutment.



**Figure 19.** A permanent abutment sleeve was placed to facilitate the use of an all-ceramic (cerabase) abutment. Screw access was palatal to the adjacent incisal edges.



**Figure 20.** The all-ceramic cerabase abutment was placed on the laboratory model.



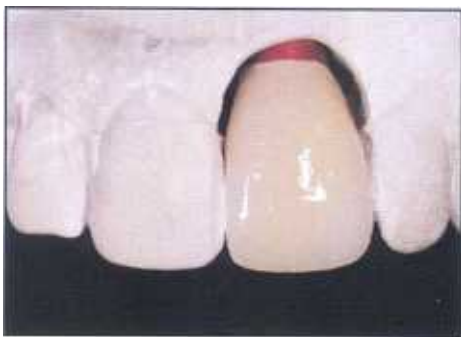**Figure 21.** The all-ceramic abutment was placed on the soft tissue model prior to preparation of the final abutment chamfer line.

(approximately 80g to 120g) and the teeth should demonstrate no sign of inflammation or periodontal or periapical pathology. Following stabilization, extraction and immediate implant placement are suggested (Figure 11).<sup>7</sup>

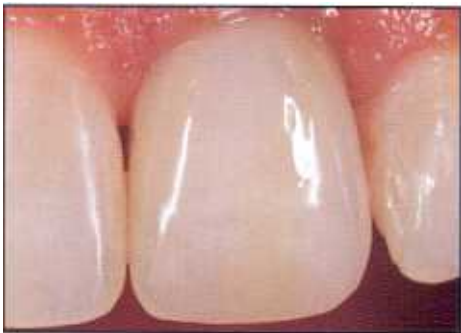To account for potential recession and shrinkage of the hard and soft tissues following surgery, the authors recommend approximately 20% to 25% overcorrection of the site prior to extraction and immediate implant placement (Figure 12). Following atraumatic extraction, it is necessary to once again reevaluate the site utilizing the aforementioned bone sounding techniques. Selection of the appropriate implant diameters, shape, and thread design then becomes paramount in managing the implant site. A tapered implant system with different anatomic diameters may allow for a true anatomic reconstruction beginning at the neck of the implant and may allow for an enhanced engagement of the tapered implant to the tapered extraction site. As with other implant systems, this allows for atraumatic surgical placement — in many

cases without the need for raising a flap — and avoids stripping of the periosteum and compromising the vascularity of the buccal plate. Utilization of this technique can provide the practitioner with a shorter, simplified, and more efficient approach to management of tooth replacement procedures in the anterior region. Clinicians have been utilizing this technique since 1996 with the results comparable to traditional single-stage implant techniques (Figure 13).

Once orthodontic treatment has optimized the site and overcorrected the hard and soft tissue dimensions vertically, the teeth are extracted with periostomes in an atraumatic method. The periodontal ligament spaces should be engaged in an apical direction to slowly tear those fibers and release the tooth without destruction or pressure of standard elevators to the surrounding socket and bony walls (Figure 14). Once the tooth is extracted, the extraction site is internally and externally evaluated via bone sounding (Figures 15 and 16). In the absence



**Figure 22.** Following porcelain application, the subgingival area was minimized to avoid excessive apical placement of the implant-crown interface.



**Figure 23.** Postoperative view following placement of the single-tooth implant restoration demonstrates enhanced aesthetics, soft tissue scallop, height of interdental papilla, and overall soft tissue health.

of fenestrations, an appropriate anatomic diameter implant is selected to engage the mesiodistal walls of the socket based on the mesiodistal diameter of the extraction socket. Custom anatomically shaped healing abutments can be fabricated chairside with acrylic or composite resin when necessary to maintain or condition the soft tissue during the osseointegration phase of healing (Figures 17 and 18).<sup>8</sup> Careful attention should be taken to ensure that the implant is placed slightly to the palatal aspect in order to avoid trauma to the buccal plate and allow for a screw access that promotes the utilization of aesthetic ceramic abutment systems or opacious porcelains that conceal the metallic substructure of the implant components (Figures 19 through 23).

## Conclusion

When planning for tooth replacement in the aesthetic zone, selection of an appropriate restoration is exceptionally

challenging. The authors suggest that preoperative diagnostic evaluation of the site utilizing bone sounding and radiographic evaluation will enable selection of the most appropriate restorative procedure for a predictable aesthetic result. When evaluating a deficient site prior to extraction, utilization of adjunctive orthodontic extrusion will facilitate manipulation of the surrounding attachment apparatus prior to extraction and implant placement. This technique allows for utilization of the patient's own bone and soft tissue in a nonsurgical approach that enhances the implant site vertically and provides for an atraumatic extraction with immediate implant placement. Treatment can be achieved in a single surgical phase (in many instances) and can be managed without the reflection of a surgical flap to facilitate expeditious healing and predictable soft tissue support and contours for the final restorative phase. In addition, this nontraumatic implant placement technique allows for maintenance of the vascularity to the critical labial plate of bone and minimizes the potential for postoperative soft tissue recession.

## Acknowledgment

*The authors declare no financial interest in any of the products cited herein.*

## References

1. Tarnow DP, Magner AW, Fletcher P. The effect of the distance from the contact point to the crest of bone on the presence or absence of the interproximal dental papilla. *J Periodontol* 1992;63(12):995-996.
2. Kois J. Altering gingival levels: The restorative connection. Part I. Biologic variables. *J Esthet Dent* 1994;6:3-9.
3. Salama H, Salama MA, Garber DA, Adar P. The interproximal height of bone: A guidepost to predictable aesthetic strategies and soft tissue contours in anterior tooth replacement. *Pract Periodont Aesthet Dent* 1998;10(9):1131-1141.
4. Tarnow DP. The effect of inter-implant distance on the height of inter-implant bone crest. *J Periodontol* 2000;71(4):546-549.
5. Salama H, Garber DA, Salama MA. The periodontal issues in smile design. Presented at the Academy of Periodontology Annual Meeting, September 17, 2000; Honolulu, HI.
6. Salama H, Salama MA. The role of orthodontic extrusive remodeling in the enhancement of soft and hard tissue profiles prior to implant placement: A systematic approach to the management of extraction site defects. *Int J Periodont Rest Dent* 1993;13(4):312-333.
7. Wöhrlé PS. Single-tooth replacement in the aesthetic zone with immediate provisionalization: Fourteen consecutive case reports. *Pract Periodont Aesthet Dent* 1998;10(9):1107-1114.
8. Wheeler S, Vogel R, Casellini R. Tissue preservation and maintenance of optimum esthetics: A clinical report. *Int J Oral Maxillofac Impl* 2000;15(2):265-271.

# CONTINUING EDUCATION (CE) EXERCISE No. 5

To submit your CE Exercise answers, please use the answer sheet found within the CE Editorial Section of this issue and complete as follows: 1) Identify the article; 2) Place an X in the appropriate box for each question of each exercise; 3) Clip answer sheet from the page and mail it to the CE Department at Montage Media Corporation. For further instructions, please refer to the CE Editorial Section.

The 10 multiple-choice questions for this Continuing Education exercise are based on the article "Guidelines for aesthetic restorative options and implant site enhancement: The utilization of orthodontic extrusion" by Maurice A. Salama, DMD, Henry Salama, DMD, and David A. Garber, DMD. This article is on Pages 125-130.

## Learning Objectives:

This article presents the utilization of orthodontic extrusion in combination with atraumatic extraction and immediate implant replacement utilizing a tapered implant system. Upon reading this article and completing this exercise, the reader should:

- Demonstrate an awareness of the anatomical and biological considerations during immediate extraction and implant placement.
- Understand the diagnostic indicators of orthodontic extrusion.

### 1. The selection of the appropriate tooth replacement technique should be aided by prediagnostic:

- Subgingival cultures.
- Level of periodontal disease.
- Preoperative bone sounding.
- Location of decay in surrounding teeth.

### 2. The area of bone sounding that helps to predict the future soft tissue papilla levels is found on what aspect?

- Palatal.
- Facial.
- Sublingual.
- Interproximal.

### 3. Teeth slated for extraction and implant replacement with inadequate volume of bone and soft tissue can best be augmented prior to extraction by utilization of what technique?

- Orthodontic extrusion.
- Periodontal plastic surgery.
- Autogenous block grafting.
- Placement of subgingival antibiotics.

### 4. Orthodontic augmentation techniques work by utilizing what anatomical and biological rationale?

- PRP.
- BMP.
- Guided tissue regeneration.
- Tension on the periodontal ligament.

### 5. What levels of orthodontic forces are best applied for orthodontic extrusion prior to extraction?

- 20 grams to 50 grams of force.
- 80 grams to 120 grams of force.
- 120 grams to 150 grams of force.
- 200 grams to 250 grams of force.

### 6. To account for potential recession and shrinkage of the hard and soft tissues following immediate implant placement, the authors recommend approximately what percentage of overcorrection of the site?

- 10% to 15%.
- 20% to 25%.
- 50% to 55%.
- 95% to 100%.

### 7. What implant shape was recommended by the author to replace immediately extracted teeth?

- Narrow.
- Press fit.
- Tapered.
- Cylindrical.

### 8. When planning to place implants at the time of extraction, it is best to first:

- Place antibiotics into the extraction site.
- Prepare the osteotomy for the implant.
- Bone graft the site prior to implant placement.
- Internally and externally evaluate the extraction site via bone sounding.

### 9. Custom anatomically shaped healing abutments placed at the time of immediate implant placement helps to:

- Idealize osseointegration.
- Increase the stability of the implant.
- Condition and shape the surrounding soft tissues.
- Allow for proper shade selection for the definitive crown.

### 10. What clinical armamentarium was suggested to manage tooth extractions in the aesthetic zone prior to immediate implant replacement?

- Osteotomes.
- Endoscopes.
- Periotomes.
- Periodontal probes.