

## Intraoral Cameras Help Predict and Prevent Tooth Loss

For many decades, the dental profession has enjoyed a high ranking on most consumer opinion polls. However in recent years the dental profession's public image has decreased considerably in the polls.<sup>1-3</sup> Perhaps some of this decrease can be traced to a misleading article, and even more misleading treatment of the profession, which was published by *Reader's Digest* magazine in February 1997.<sup>4</sup> Not only was the story fraught with inaccuracies, but the fact that *Reader's Digest* decided to publicize this article with a false bright red cover and bright yellow headlines, "Exclusive Investigation—How Dentists Rip Us Off," carried an even stronger negative message about the dental profession to American consumers.

The overwhelming negative response to this story was addressed and well publicized in dental periodicals, and its conclusions were universally condemned by the profession. However, the nature of the article, which pointed out different diagnoses made by various dentists examining the same patient, makes our job of diagnosis even more difficult and ever more important today.

Fortunately, there is one technology that helps us bridge the gap in communication and allows the patient to become a "codiagnostician" throughout diagnosis and treatment. This involves a "video exam" or a tooth-

by-tooth examination using the intraoral camera.<sup>5,6</sup> This special-focus examination identifies pathology that even patients can easily see when pointed out by the dentist. Furthermore, it allows the dentist to assume a proactive role in predicting what may happen as a result of certain existing findings. This article reviews the advantages of intraoral photography, the basic steps of using this type of diagnostic aid, and how to communicate the findings to the patient.

*The video examination is an effective means of reestablishing trust between patient and dentist by making the patient a codiagnostician.*

The intraoral examination should be performed quadrant by quadrant, air-drying the teeth to be examined before using the camera. Air-drying reduces light reflection and promotes a sharper image on the monitor. The patient's head should be somewhat facing the monitor so he or she can have the same viewpoint as the dentist.

The dental assistant should be seated near the patient's head but should also be able to view the monitor (Figure 1). There is a special advantage for the dental assistant to hold and use a laser light pointer. With this technique, the dentist can maintain a steady intraoral position with the camera, especially if the dentist's

left hand is holding the patient's cheek. The red laser light is especially effective in pointing out defects on the monitor. In addition to pointing out conditions to the patient, the assistant can simultaneously write the findings and proposed treatment on a treatment sequence sheet. The fact that the assistant uses the pointer reinforces to the patient that the assistant understands and recognizes exactly what the dentist sees.

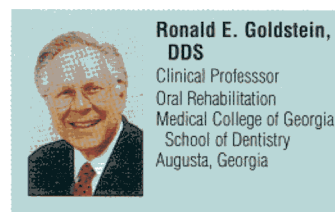
During the examination the

dentist should pay special attention to the presence of five conditions:

1. caries
2. microcracks
3. other defects
4. faulty restorations
5. periodontal pathology

### CARIES

Gross caries should be shown to the patient and easily understood. All surfaces (ie, labial, occlusal, lingual, as well as interproximal surfaces) can be seen and should be viewed with the camera. However, beginning caries or questionable areas should also be shown to the patient and documented for possible action or reevaluation at a later

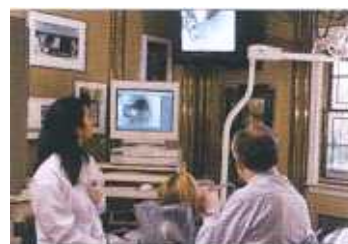

**Ronald E. Goldstein, DDS**  
Clinical Professor  
Oral Rehabilitation  
Medical College of Georgia  
School of Dentistry  
Augusta, Georgia

date. Images showing the pathology can be saved and stored electronically as well as printed for the patient if desired.

### MICROCRACKS (FRACTURE LINES)

Perhaps the most important use of the intraoral camera is for the transillumination of the tooth as it records fracture lines.<sup>7</sup> Microcracks, or fracture lines, are easily seen by varying the light intensity and the angle at which the camera captures the tooth surface. A simple occlusal amalgam with the microcrack emitting light through the marginal ridge can be a possible beginning of future tooth loss—particularly if the patient bites on a hard object exactly in the weak point of the fractured area.



*Figure 1—It is important for the patient to be able to see exactly what you and your assistant see, in order to become a codiagnostician.*

The intraoral examination should be performed quadrant by quadrant, air-drying the teeth to be examined before using the camera.

Explain to the patient that a fracture line in a tooth can be compared to a block of wood. If a hatchet chips down the center, the wood can split. Similarly, a tooth with a vertical fracture line can also split if the patient bites hard on a blackberry seed or any hard object (eg, ice or a hard crust of bread).

Patients should know the potential for tooth loss or tooth fracture, and the intraoral camera makes it easy to understand the need to replace or correct the restoration. One of the most important benefits of performing a video examination is in providing a proactive stance for the patient, which, in turn, makes it possible for the patient to choose to correct faulty conditions and prevent unnecessary tooth loss or severe tooth fracture. However, in the event the patient chooses not to do so, he or she has been forewarned. Bacteria can also be harbored in this cracked area and not show on the radiograph, again pointing to the possible need for tooth restoration or replacement.

Certainly not every microcrack needs to be corrected and, in fact, most do not. However, it

is the responsibility of the dentist to help predict which microcracks may eventually cause a problem for the patient. Furthermore, patients who desire to have tooth whitening should be warned if there are microcracks in their teeth. Microcracked areas may absorb more of the whitening agent and not provide a uniform lightening effect.

#### OTHER DEFECTS

Defective pits or fissures are usually stained and these should be pointed out to the patient. A cavity-detecting laser or a caries-detecting solution or gel followed by removing the stain with air-abrasion may also help identify caries. Stains should be pointed out to the patient, and if the intraoral examination is scheduled before a prophylaxis, a note should be made to reevaluate the stain after prophylaxis.

#### FAULTY RESTORATIONS

A defective restoration can sometimes be seen via stains at the margin of the restoration and pointed out to the patient, especially if it is a tooth-colored restoration. Sometimes, the defect itself is apparent as a result of too

much wear in the restoration and the enamel not being supported by the restoration. The intraoral camera also makes it easy for both the dentist and patient to see defective margins, corrosion, or fractures in an amalgam sealant.

#### PERIODONTAL PATHOLOGY

The video examination is of special value in showing the patient the difference (if any) in color between his or her healthy tissue and that of diseased gingival tissue. In addition, areas of the cheek and hard and soft palates should be examined with the patient observing.

Perhaps the greatest value of an intraoral examination is its ability to show the patient the results of probing a periodontal pocket. Many times exudates can be seen, which dramatically affects the patient's acknowledgment that disease does exist.

#### TERMINOLOGY

Using the term "video exam" is usually not threatening to the patient, plus it also has an easy-to-understand, pleasant-sounding name to it. On the other hand, if you tell the patient that you are going to do an examination with an intraoral camera, it may carry a more clinical and even "invasive" perception. The entire atmosphere of a "video examination" takes on a more nonthreatening, discovery- or exploration-oriented, fun atmosphere for the patient. And in the process, the patient's dental IQ is enhanced considerably.

#### SUMMARY

The video examination is an effective means of reestablishing trust between patient and dentist by making the patient a codiagnostician. In fact, it is not uncommon for patients to stop the diagnosis and ask specific questions about what they see. In this way, patients can begin to diagnose pathology even before the dentist mentions it. A major benefit of the video examination to the dentist is that invariably the examination reveals conditions not seen in typical clinical examinations—even when using magnification loops. Although the intraoral camera has existed for more than a decade, its benefit during the video examination is more important now than ever before.<sup>8,9</sup> ○

#### REFERENCES

1. Gallup Organization: *How Dentists Rate On Honesty, Ethics*. Dental Practice Report, 8(3):11, 2000.
2. McAneny L: *Nurses Displace Pharmacists at Top of Expanded Honesty and Ethics Poll* [press release]. Gallup Poll Release. November 16, 1999.
3. Gallup Poll Topics: *A-Z Honesty / Ethics in Professions*. The Gallup Organization website. Available at: [http://www.gallup.com/poll/indicators/industry\\_ethics.asp](http://www.gallup.com/poll/indicators/industry_ethics.asp). Accessed September 5, 2001.
4. Eckenbarger W: *How Honest Are Dentists? Reader's Digest*, p 50, February 1997.
5. Goldstein CE, Goldstein RE, Garber DA: *The Intraoral Camera*. In: *Imaging In Esthetic Dentistry*. Quintessence, Carol Stream, IL, p 15-28, 1998.
6. Goldstein RE: *Esthetics in Dentistry*. B.C. Decker, Inc., Hamilton, Ontario, p 27-28, 1998.
7. Levin RP: Building your practice with an intraoral video camera. *Compend Contin Educ Dent* 11(1):52-56, 1990.
8. Lackey AD: Intra-oral video photography: questions and answers. *J Calif Dent Assoc* 19(3):29-32, 1991.
9. Goldstein RE, Miller MC: High technology in esthetic dentistry. *Curr Opin Cosmet Dent* 5-11, 1993.